


# Impact of upper blepharoplasty, with or without orbicularis oculi muscle removal, on tear film dynamics and dry eye symptoms: A randomized controlled trial

Maria H. J. Hollander,<sup>1</sup>  Jan Willem R. Pott,<sup>2</sup> Konstantina Delli,<sup>1</sup> Arjan Vissink,<sup>1</sup> Rutger H. Schepers<sup>1</sup> and Johan Jansma<sup>1</sup>

<sup>1</sup>Department of Oral and Maxillofacial Surgery, University of Groningen and University Medical Center Groningen (UMCG), RB Groningen, The Netherlands

<sup>2</sup>Department of Ophthalmology, University of Groningen and University Medical Center Groningen (UMCG), RB Groningen, The Netherlands

## ABSTRACT.

**Purpose:** Upper blepharoplasty may be related to dry eye symptoms since the function of the orbicularis oculi muscle may affect the tear film. We aimed to assess the effect of blepharoplasty with or without the removal of a strip of orbicularis oculi muscle on tear film dynamics and dry eye symptoms.

**Methods:** A double-blind, randomized, controlled trial comparing upper blepharoplasty without (group A) or with (group B) orbicularis oculi muscle excision was performed on 54 healthy Caucasian patients. Tear film dynamics and dry eye symptoms were evaluated using multiple dry eye parameters, i.e. tear osmolarity, Schirmer test I, corneal/conjunctival staining, tear break-up time (TBUT), Oxford Scheme, Sicca Ocular Staining Score and Ocular Surface Disease Index questionnaire. All the parameters were assessed preoperatively and 6 and 12 months after upper blepharoplasty. All the groups' outcomes were compared.

**Results:** The differences were not significant between the two upper blepharoplasty techniques regarding most of the above-mentioned outcomes. Subjective symptoms of ocular irritation, consistent with dry eye disease and vision-related impairment, were reduced after upper blepharoplasty independent of the type of the technique applied, while the pre and postoperative outcomes of the objective tear dynamics did not differ 12 months after surgery. However, group B demonstrated a significant increase in tear osmolarity and TBUT at the 6-month follow-up visit.

**Conclusion:** An upper blepharoplasty alleviates subjective dry eye complaints in the long term, while not changing the tear dynamics. The improvement was independent of the blepharoplasty technique used.

**Key words:** blepharoplasty – dryeye – osmolarity – OSDI – conjunctivalstaining – Schirmer – eyelid correction – tear film – TBUT

Study design: M.H.J.H., J.W.R.P., A.V., R.H.S., J.J. Enrolment of participants (including eligibility): M.H.J.H., R.H.S., J.J. Data collection: M.H.J.H. Data-processing and analysis: M.H.J.H., A.V., K.D. Preparation of manuscript: M.H.J.H., J.W.R.P., K.D., A.V., R.H.S., J.J.

Acta Ophthalmol.

© 2021 Acta Ophthalmologica Scandinavica Foundation. Published by John Wiley & Sons Ltd

doi: 10.1111/aos.15036

## Introduction

Dry eye disease is a common multifactorial disease of the ocular surface. Dysfunction of any component of the lacrimal functional unit, such as decreased tear production, increased evaporative loss and changes in drainage, can result in dry eye symptoms. Dry eyes can be divided into two primary categories: aqueous tear-deficient and evaporative. The first type involves the failure of lacrimal secretion and water secretion. The second type involves excessive water loss due to tear film instability. Dysfunction can be caused by a variety of iatrogenic interventions, such as ophthalmic surgical procedures including upper blepharoplasty (Gomes et al. 2017).

A traditional upper blepharoplasty entails the removal of excess skin together with a strip of orbicularis oculi muscle, sometimes combined with excision or redistribution of fat from the medial and central fat compartments. Nowadays, the preservation of youthful fullness on the upper eyelids is gaining more attention with surgeons tending to be more conservative during upper blepharoplasties by sparing the orbicularis oculi muscle and orbital fat (Rohrich et al. 2004; Gulyas 2006; van der Lei et al. 2007; Fagien 2010).

About 13% of the patients experience dry eye symptoms after an upper

blepharoplasty (Prischmann et al. 2013). There is still a lot of uncertainty regarding the relationship between dry eye disease and upper blepharoplasty, in general, but various mechanisms have been proposed to explain the association. Specifically, it has been suggested that an upper blepharoplasty may change the relative position of the eyelid, thereby mechanically altering the corneoscleral and conjunctival interface (Zhang et al. 2020). Another explanation attributes dry eye symptoms to the close interaction between the eyelids, lacrimal pump and tear film (Zhang et al. 2020). The lacrimal pump mechanism is intimately associated with the orbicularis muscle function. The tear fluid passage support mechanism is the tear pump, stimulated by orbicularis oculi muscle contraction, namely when the pretarsal and preseptal muscles close the eyelids. When the pretarsal muscle contracts and shortens, the canaliculi squeeze tears into the lacrimal sac while the muscle pulls the lacrimal sac laterally and forward, creating a vacuum to draw the tears into the sac. Upon relaxation, tears are driven into the nasolacrimal duct (Maliborski & Rozycky 2014; Tong et al. 2021).

In theory, violating the orbicularis oculi muscle during an upper blepharoplasty may lead to blink alterations, which might account for decreased mechanical tear film distribution, reduced outflow of lipid secretion from the meibomian glands, and reduced tear drainage with impaired debris removal from the ocular surface (Gomes et al. 2017; Zhang et al. 2020). This, in turn, may cause irritation and/or dry eye symptoms. On the contrary, the correction of abundant tissue of the upper eyelid may also improve mechanical eyelid function and alleviate dry eye complaints.

However, it is still not set in the literature whether resecting additional orbicularis oculi muscle during an upper blepharoplasty affects the tear film or dry eye symptoms (Hollander et al. 2019).

To the best of our knowledge, no study has been published so far comparing the tear film dynamics and dry eye symptoms in patients undergoing a skin only upper blepharoplasty and patients with additional removal of orbicularis oculi muscle. Therefore, we aimed to compare the effect of the two blepharoplasty techniques on tear film dynamics and dry eye symptoms in patients.

## Methods

### Study population

All consecutive Caucasian patients, between 30 and 70 years of age, who consulted the department of Oral and Maxillofacial Surgery at the University Medical Center Groningen for an upper blepharoplasty between February 2018 and October 2019 and spoke Dutch fluently, were asked to participate (Fig. 1). The consultations were performed by two maxillofacial surgeons (J.J., R.H.S.) with extensive experience in upper blepharoplasties. Patients were included if they showed dermatochalasis of both upper eyelids, and an upper eyelid blepharoplasty was indicated. Indications for upper eyelid blepharoplasty included excess upper eyelid skin that resulted in functional symptoms or cosmetic concerns in patients. The indication for blepharoplasty in this study was predominantly cosmetic, while patients often reported a heavy feeling of the eyelids. Only one patient complained about visual symptoms (limited upper peripheral vision).

Patients were excluded if they had a history of ocular or orbital trauma, had a history of eyelid surgery or surgery in the region of the eyebrows, had been

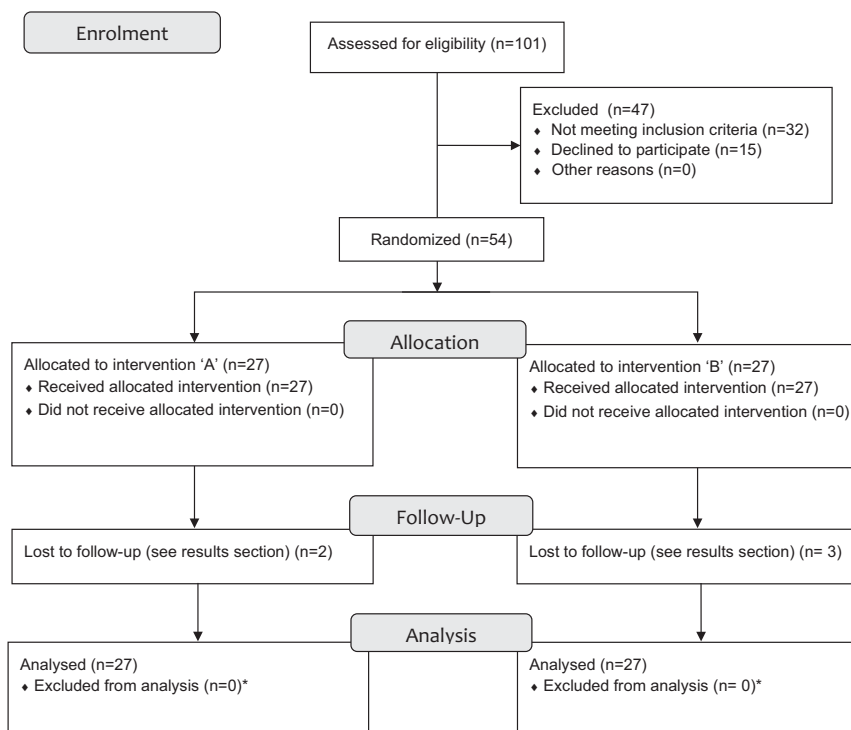


Figure 1. Flow diagram of participant enrolment. \*Only the 'lost to follow-up' missing values were excluded from analysis.

subjected to other cosmetic surgical or non-surgical procedures, had a current or history of ophthalmic disease, suffered from blepharoptosis or any (systemic) disease or condition that could interfere with the ophthalmic tests.

### Study design

A prospective, single-centre, double-blind, randomized, controlled trial investigating dry eye parameters before and after upper blepharoplasty. The study protocol was approved by the institutional review board (METc2017/451) and registered in the Netherlands Trial Register (ID NL7886). Written informed consent was obtained from all the study participants.

### Blinding and randomization

Eligible participants were randomly assigned to treatment group 'A' (resection of skin only) or 'B' (resection of skin and a strip of underlying orbicularis oculi muscle). Randomization was performed by creating a blocked randomization list before the start of the study with a web-based randomization system ([www.sealedenvelope.com](http://www.sealedenvelope.com)). The participants received a unique code in consecutive order, i.e. the first included participant received the first code on the list. The investigators and participants were blinded. Only the surgeons knew which treatment was given to the participants until completion of the trial. The participants were informed about both surgical procedures but did not know which treatment they underwent. All the patients received identical information about the procedure and post-operative course.

### Outcomes

Demographic data were recorded including age, gender, medical history, use of medication and use of contact lenses. The severity of the upper eyelid dermatochalasis was assessed before the upper blepharoplasty and categorized according to a 4-level photonumerical severity scale using anatomical cut-off points, i.e. normal if the upper eyelid skin was not touching the eyelashes, mild if the upper eyelid skin was touching the eyelashes, moderate if the upper eyelid skin was hanging over the eyelashes and severe if the upper eyelid skin was hanging over the eye (Jacobs

et al. 2014). The removed tissue was weighed per eye and recorded in grams.

The study outcomes were evaluated preoperatively, and 6- and 12-months post-blepharoplasty. All the tests were performed on both eyes by the same researcher (M.H.J.H.), who was blinded for the surgical procedure. All dry eye tests were performed under identical circumstances and were performed in the following sequence: tear osmolarity, Schirmer test I, fluorescein staining and TBUT and Lissamine green staining. The patients also underwent a detailed ophthalmic examination, including best corrected visual acuity and the presence of blepharitis, meibomian gland dysfunction, ocular mucin, ectropion/entropion and other eyelid abnormalities (except dermatochalasis).

#### a) Tear osmolarity

Tear osmolarity was evaluated using the Tearlab osmolarity system (OcuSense, Inc, San Diego, CA). This test utilizes a temperature-corrected impedance measurement to provide an indirect assessment of osmolarity. A 50 nl tear sample was collected from the lateral meniscus of each eye at least 15 min after using the slit lamp (ophthalmic examination). Tear hyperosmolarity is considered a biomarker for dry eye disease (Willcox et al. 2017). In healthy people, the mean tear osmolarity is 298 mOsm/l (Baenninger et al. 2018) and 308 mOsm/l or more in dry eye disease cases (Wolffsohn et al. 2017).

#### b) Schirmer test I

The Schirmer test I measures total tear secretion, including reflex and basal tears. A folded test strip of sterile filter paper, supplied in a standard kit, was placed over the margin of each lower eyelid at the junction of the middle and lateral thirds, without prior application of anaesthetic eye drops. The extent of wetting was measured by leaving the paper on the lower eyelid for 5 min, held in place by the patients gently closing their eyes. The paper was then removed and the amount of paper wetting in millimetres was recorded per eye. It is generally agreed that a Schirmer I test of  $\leq 5$  mm in 5 min is abnormal (Bron et al. 2007).

#### c) Cornea staining

Fluorescein dye was used to stain areas of discontinuity in the epithelial surface of the cornea. Corneal and

conjunctival surfaces are stained whenever there is a disruption of cell-to-cell junction (Feenstra & Tseng 1992). A sterile strip of fluorescein was moistened with sterile NaCl. The NaCl was allowed to just saturate the impregnated tip, at which point the excess was immediately shaken free into a waste bin. The moistened strip was then applied to the conjunctival fornix of the eye. The cornea was observed under a cobalt blue filtered light from a slit lamp microscope. Punctate epithelial erosions (PEE) on the cornea that stain with fluorescein were counted and scored with the SICCA ocular staining score and the Oxford Scheme. This was repeated for the contralateral eye.

#### d) Tear break-up time (TBUT)

TBUT was also measured with the fluorescein to determine tear film stability. A TBUT of  $\leq 10$  seconds is abnormal and indicative of a deficiency or abnormal quality of the outermost mucus layer of the tear film (Lemp et al. 2011). The subjects were asked to blink three times and then to look straight ahead without blinking. The tear film was observed under the cobalt blue filtered light of the slit lamp microscope and the time that elapsed between the last blink and appearance of the first break in the tear film was recorded in seconds. This was measured three times and the mean value was used for further analysis.

#### e) Conjunctival staining

A sterile strip of lissamine green was moistened in the same way as the fluorescein strip and placed in the conjunctival fornix of the eye. The subjects were asked to blink a few times after which the eyes were examined and graded directly. The staining was evaluated with the help of the slit lamp ( $\times 16$  magnification) using a neutral density filter over the light source to avoid blanching of the conjunctiva. The temporal area of the conjunctiva was observed while the subject looked nasally along the horizontal plane, and the nasal conjunctiva was observed while the subject looked temporally. Conjunctival staining with lissamine green was evaluated by the amount of visible punctate staining on the conjunctiva and by using the Oxford Scheme (Bron et al. 2003) and the SICCA Ocular Staining Score (Whitcher et al. 2010).

#### f) The Oxford scheme

The Oxford Scheme, which has been specifically developed to quantify epithelial surface damage in case of dry eyes, involves a chart with a series of panels labelled A–E (grade 0 to V) in order of severity (absent, minimal, mild, moderate, severe) (Bron et al. 2003). The whole exposed ocular surface was considered, without separating the cornea and the conjunctiva, and the number of dots representing the staining increased logarithmically.

#### g) Ocular staining score

A quantitative dry eye grading scheme was developed as part of SICCA (Sjögren's International Collaborative Clinical Alliance): the Ocular Staining Score (OSS; Whitcher et al. 2010). It uses lissamine green to grade the conjunctiva and fluorescein to grade the cornea.

Regarding the cornea, the score is 0 if there is no PEE. Counts of 1–5 PEE are scored as 1; 6–30 PEE are scored as 2; and >30 PEE are scored as 3. An additional point was added if (1) PEE occurred in the central 4 mm diameter portion of the cornea; (2) one or more filaments were seen anywhere on the cornea; or (3) one or more patches of confluent staining, including linear stains, were found anywhere on the cornea. The total fluorescein score for the cornea (the PEE grade plus any extra points for modifiers) was noted in the central square of the SICCA ocular staining score form. The maximum possible score for each cornea was 6.

Regarding the conjunctiva, grade 0 was defined as 0–9 dots of Lissamine green staining; grade 1 was defined by the presence of 10–32 dots; grade 2 by 33–100 dots; and grade 3 > 100 dots. The total OSS for each eye was the summation of the fluorescein score for the cornea and the lissamine green scores for the nasal and temporal conjunctiva. Therefore, the maximum possible score for each eye was 12. The eyes were graded separately and the scores recorded on the SICCA ocular staining score form.

#### h) Ocular surface disease index (OSDI) questionnaire

The OSDI is a validated 12-item questionnaire designed to provide an assessment of the symptoms of ocular irritation consistent with dry eye disease

and their impact on vision-related functioning (Schiffman et al. 2000). The questionnaire has 3 subscales: ocular symptoms, vision-related function and environmental triggers. Our patients rated their responses on the 0–4 scale with 0 corresponding to 'none of the time' and 4 corresponding to 'all of the time'. A final score was calculated with a formula, which could range from 0 to 100, with scores 0–12 representing normal, 13–22 representing mild dry eye disease, 23–32 representing moderate dry eye disease and greater than 33 representing severe dry eye disease.

#### Surgical procedure

The upper blepharoplasties were performed by two surgeons (J.J., R.H.S.) and took place in an outpatient environment. The surgical procedure was standardized before the study. The patients underwent either the removal of upper eyelid skin only procedure (group A) or the additional removal of a strip of orbicularis oculi muscle (group B). The surgical landmarks and planned skin excisions were marked on the upright positioned patient's eyes. Approximately 1.7 ml of ultracaine DS Forte (40 mg articaine, 10 µg epinephrine per ml) local anaesthetic was injected subcutaneously per eye. After the skin incision with a scalpel, the marked excess skin was removed. The group B participants underwent subsequent removal of an additional strip of the underlying orbicularis oculi muscle (3–4 mm). The orbital septum was coagulated, and the muscle edges were approximated with bipolar coagulation. The skin was sutured with ethilon 6-0 (Ethicon, Cornelia, Georgia, USA) intracutaneously in a running fashion, and adhesive suture strips were placed. All the other steps of the procedure were identical for both groups of A and B.

When indicated, i.e. when a significant amount of protruding medial fat was present, this protruding medial fat was removed after minimally opening the orbital septum.

#### Statistical analysis

Sample size calculations were based on tear osmolarity. All the measurements were carried out per eye and not by averaging both eyes in one participant. A total of 27 patients (54 eyes) were needed per treatment group to detect a

difference of 10 mOsm/l (G\*Power version 3.1.9.6, University of Kiel, Germany) between groups A and B (the mean osmolarity of a normal tear film is 298 mOsm/l according to the Baenninger et al. systematic review (2018); and >308 mOsm/l for DED according to the Dry Eye Workshop Report 2017 (Wolffsohn et al. 2017), with a two-sided 5% significance level and power of 90%, allowing for a 10% attrition rate and 10% for possible non-parametric testing.

The data was analysed using IBM SPSS Statistics version 23.0 (IBM Corp., Armonk, NY, USA). Shapiro–Wilk test, Kolmogorov–Smirnov test and graphical interpretation of Q–Q plots were used to determine the distribution of the data. Independent samples t-test, Chi-squared test and Fisher's exact test were used where appropriate to test baseline differences between the groups.

The differences between group A's and B's tear osmolarity, Schirmer test, TBUT, SICCA OSS, Oxford scheme and OSDI-questionnaire scores were evaluated using generalized estimating equations (GEE). The GEE model included the postoperative outcomes, baseline scores, gender, age, dermatochalasis severity score, amount of removed tissue during surgery, the use of contact lenses and medication used with possible effect on tear secretion or dry eye symptoms (Prischmann et al. 2013; Wolff et al. 2017). p-Values < 0.05 were considered statistically significant. Missing data were not imputed. All the residuals showed a Gaussian distribution. Different correlation structures (exchangeable, M-dependent, unstructured) were tested and the model with the lowest information criterion was used, which was the M-dependent correlation structure for the tear osmolarity and the exchangeable correlation structure for all the other variables.

Pre- and post-blepharoplasty differences were analysed using the Friedman test, and pairwise comparisons were performed whereupon Bonferroni adjusted p-values were applied. Each group's postoperative scores were compared with the baseline scores.

## Results

A total of 54 patients was enrolled, and 108 eyes were evaluated. The

characteristics of the included patients are shown in Table 1. Group A's and B's characteristics were comparable at baseline. A total of 5 female patients' data were excluded: two group B patients were lost to follow-up at 2 months and 12 months; two group A patients were excluded after the 6-month follow-up visits due to burn-out and to health problems related to dysregulated diabetes mellitus; and one group B patient was excluded from the 12-month analysis because of her wish to correct the scar tissue on one eyelid after the initial procedure. The latter patient sutures had become loose which resulted in a widened scar that was corrected after the 6-month follow-up visit. The medications used by the participants, which did not change during the 12-month follow-up, are listed in Table 1. During the baseline ophthalmic examination, one patient displayed very mild asymptomatic conjunctivochalasis (group A) which did not progress during the study. No other abnormalities were observed. None of the patients used artificial tears, eye drops or ointment before or during the course of the study. The use of any contact lenses or contact lens solution was not altered during the

study. Participants did not undergo any other ophthalmic surgery or treatment before and during the course of the study.

**Objective outcomes**

There were no significant differences between groups A and B at the 6-month and 12-month follow-ups regarding all primary outcomes (Table 2). A significant increase in tear osmolarity (median increase = 10 mOsm/l,  $p = 0.037$ ) and TBUT (median increase = 1s,  $p = 0.037$ ) was observed in group B at the 6-month follow-up but not at the 12-month follow-up. There were no significant differences in Group A's tear osmolarity and TBUT compared with baseline. Both groups' postoperative Schirmer test I was not significantly different from the baseline test. No significant differences were found between the 6- and 12-month outcomes in both groups.

**Physician rated dry eye scores**

The differences between groups A and B regarding Oxford scheme grading and OSS, at the 6-month and the 12-month follow-ups, were not significant

(Table 2). Both groups' median Oxford scheme grading was grade '0' at baseline and at 6 and 12 months postoperatively, indicating the absence of dry eye disease. The same applied to the OSS, whose median was also '0' during the postoperative assessments (6- and 12-month follow-ups). There were no significant differences between the baseline findings and the 6- and 12-month follow-ups (Table 2).

**Patient reported dry eye scores**

Generalized estimating equations (GEE) revealed no significant differences between groups A and B at the 6-month and the 12-month follow-ups regarding OSDI (Table 2). The median preoperative OSDI scores were 13 [4;27] (group A) and 17 [6;31] (group B) indicating preoperative mild dry eye disease in both groups according to the questionnaire's cut-off points (Schiffman et al. 2000). Both groups' OSDI scores decreased significantly to 'normal' (Schiffman et al. 2000) at the 6- and 12-month follow-ups. Specifically, an OSDI score of 2[0;8] (group A) and 6[3;13] (group B) during the 6-month follow-up, and 4[0;15] (group A) and 6 [2;13] (group B) during the 12-month

**Table 1.** Baseline patient characteristics after randomization

	Treatment A <i>n</i> = 27		Treatment B <i>n</i> = 27		p Value	Total <i>n</i> = 54	
Gender (number and % female)	21 (78%)		23 (85%)		0.484	44 (82%)	
Age (years; mean ± SD)	58 ± 8.6		55 ± 9.1		0.241	57 ± 8.9	
Dermatochalasis severity score (number of patients)	Right eye	Left eye	Right eye	Left eye	Right eye	Right eye	Left eye
	Normal: 0	Normal: 0	Normal: 0	Normal: 0	$p = 0.771$	Normal: 0	Normal: 0
	Mild: 11	Mild: 10	Mild: 12	Mild: 13	Left eye	Mild: 23	Mild: 23
	Moderate: 15	Moderate: 16	Moderate: 13	Moderate: 12	$p = 0.523$	Moderate: 28	Moderate: 28
	Severe: 1	Severe: 1	Severe: 2	Severe: 2		Severe: 3	Severe: 3
Removed skin (g; mean ± SD [range])	Right eye	Left eye	Right eye	Left eye	Right eye	Right eye	Left eye
	0.30 ± 0.08 [0.18–0.42]	0.32 ± 0.08 [0.21–0.51]	0.32 ± 0.11 [0.18–0.61]	0.34 ± 0.12 [0.14–0.65]	$p = 0.563$	0.31 ± 0.09 [0.18–0.61]	0.33 ± 0.10 [0.14–0.65]
Removed muscle (g; mean ± SD [range])	-	-	Right eye	Left eye	-	-	-
			0.11 ± 0.07 [0.05–0.40]	0.11 ± 0.07 [0.05–0.40]	$p = 0.703$		
Medial fat removal (no. of patients)	2*		0		$p = 0.552$	2	
Contact lenses (no. of patients regularly using contact lenses)	3		5		$p = 0.704$	8	
Any general medication use (no. of patients)	5		6		$p = 0.735$	11	
Medication use possibly affecting tear secretion (no. of patients)**	2		2		$p = 1.000$	4	

\* Removal of medial fat from both eyes.

\*\* Medication use possibly affecting tear secretion or dry eye symptoms (Prischmann et al. 2013; Wolff et al. 2017). The used medications were amitriptyline (group A), metoprolol (group A), citalopram (group B) and amitriptyline (group B).

**Table 2.** Pre and postoperative dry eye outcomes (median [Q1;Q3]) and differences between groups

	Preoperatively		6 months postoperatively			12 months postoperatively		
	Group A median [Q1; Q3]	Group B median [Q1; Q3]	Group A median [Q1;Q3] (p-value*)	Group B median [Q1;Q3] (p-value*)	Adjusted difference** between group A and B (95% CI) and p-value	Group A median [Q1;Q3] (p-value*)	Group B median [Q1;Q3] (p-value*)	Adjusted difference** between group A and B (95% CI) and p-value
Tear osmolarity (mOsm/l)	304 [294;315]	306 [295;320]	311 [303;321] (p = 0.125)	314 [308;326] (p = 0.037)	2 (-8 to 13) p = 0.673	304 [294;317] (p = 0.125)	309 [302;316] (p = 0.136)	5 (-6 to 15) p = 0.339
Schirmer test I (millimetres)	7 [5;10]	8 [5;19]	6 [3;12] (p = 0.112)	8 [5;14] (p = 0.614)	0 (-5 to 4) p = 0.940	7 [4;16] (p = 0.112)	8 [5;17] (p = 0.614)	-2 (-6 to 1) p = 0.242
TBUT (seconds)	6 [5;8]	6 [5;8]	6 [5;8] (p = 0.775)	7 [5;9] (p = 0.037)	1 (-1 to 3) p = 0.464	7 [5;0] (p = 0.775)	7 [5;9] (p = 0.146)	0 (-1 to 2) p = 0.871
Oxford Score (grade 0-5)	0 [0;0]	0 [0;0]	0 [0;0] (p = 0.358)	0 [0;0] (p = 0.087)	0 (-1 to 0) p = 0.492	0 [0;0] (p = 0.358)	0 [0;0] (p = 0.087)	0 (0-1) p = 0.676
SICCA OSS (score 0-12)	0 [0;0]	0 [0;0]	0 [0;0] (p = 0.318)	0 [0;0] (p = 1.000)	0 (-1 to 0) p = 0.425	0 [0;0] (p = 0.318)	0 [0;0] (p = 0.571)	0 (-1 to 1) p = 0.832
OSDI					questionnaire (score 0-100)	13 [4;27]	17 [6;31]	2 [0;8] (p = 0.005)
6	-4 [3;13] (p = 0.005)	(-11 to 3)	p = 0.290	4 [0;15] (p = 0.005)	6 [2;13] (p = 0.001)	-4 (-11 to 4) p = 0.306		

\* p-Value of the comparison between preoperative and postoperative outcomes within a group.

\*\* The adjusted difference is the regression coefficient from the generalized estimating equation models, which represents the difference of that outcome between the treatment groups (group A-group B), adjusted for baseline values, gender, age, dermatochalasis severity score, amount of tissue removed, the use of contact lenses and medication that might affect tear secretion.

follow-up. The 6- and 12-month scores were not significantly different.

## Discussion

Historically, upper eyelid surgery is suspected of inducing or worsening dry eye disease or complaints (Rees 1975; Prischmann et al. 2013). The current randomized controlled trial did not find any clinically meaningful or statistically significant differences in dry eye parameters in both treatment groups' objective and physician-assessed scores, i.e. skin only and skin muscle group, during a long-term follow-up (12 months) compared with baseline. Subjectively, however, the patients reported that their dry eye symptoms and vision-related impairment (OSDI questionnaire score) improved significantly. Thus, a blepharoplasty does not induce or worsen dry eye symptoms but may, potentially, alleviate subjective complaints of dry eyes. It is well described in the literature that dry eye symptoms are poorly correlated with dry eye signs (Bartlett

et al. 2015) and this discordance may be influenced by several factors such as self-perceived health, mental health, age or allergies (Vehof et al. 2017; Ong et al. 2018).

Our findings are in line with former literature on this subject (Hollander et al. 2019). Subjective dry eye complaints were reported to be alleviated by surgery, but this observation was mostly not supported by objective tests, such as the Schirmer test or TBUT (Floegel et al. 2003; Schulze 2006; Rymer et al. 2017). Vold et al. (1993) assessed whether upper blepharoplasty with skin and muscle excisions was effective in alleviating dry eye symptoms such as burning, itching, redness and foreign body sensation in the eyes. They concluded that the symptoms decreased significantly after surgery (Vold et al. 1993).

The present study primarily assessed the long-term effects of an upper blepharoplasty, whereas most studies have only assessed the short-term effects, varying from 7 days (Schulze, 2006) to 3 months (Floegel et al. 2003; Rymer

et al. 2017) or reported unstandardized patient follow-ups ranging from 1 to 132 months (Prischmann et al. 2013, Saadat & Dresner 2004). Hamawy et al. (2009) showed that 98% of the patients with dry eyes recovered fully within 8 weeks after a blepharoplasty, but they did not make a distinction between upper and lower blepharoplasty. Although we did not find any significant differences in the long-term (12 months) effects compared with baseline, it is possible that transient dry eye symptoms were present shortly after surgery.

We did find a significant increase in tear osmolarity and in TBUT during the 6-month follow-up after upper blepharoplasty with additional muscle excision. These results are conflicting since an increase in tear osmolarity indicates a more unstable tear film, whereas an increase in TBUT suggests better tear film stability and quality of the outermost mucus layer. We could not find any significant association between osmolarity and TBUT in the literature (Mathews et al. 2017). In theory, our

findings could be explained by an underlying mechanism of increased evaporation postoperatively due to a more exposed ocular surface leading to hyperosmolarity. None of our patients showed lagophthalmos. The small improvement in TBUT postoperatively might be attributable to an improved eyelid function after removing the redundant eyelid skin. In the introduction, we mentioned the theory that resecting the orbicularis oculi may induce dry eye symptoms. On the contrary, the excess eyelid tissue might mechanically hinder the optimal eyelid function preoperatively, and when the excess tissue is corrected, the eyelid function becomes more optimal and mild subjective dry eye complaints (and TBUT) improves. However, this theory has to be supported by further research.

Also, the normal day-to-day variation in TBUT is 3 seconds (30.2% of dynamic range of 10s) in mild/moderate dry eye patients (Sullivan et al. 2012). This suggests that the pre and postoperative differences in TBUT are not clinically relevant.

A limitation of our study is that it only focuses on long-term ophthalmic effects. The question arises whether the changes in tear osmolarity and TBUT were more pronounced shortly after surgery. Therefore, it might be interesting to incorporate the short-term effects of upper blepharoplasty in future studies when assessing dry eyes. Another limitation of this study is that we did not evaluate tear clearance rate, which might have provided further insight into the effects of resecting the orbicularis oculi muscle during upper blepharoplasty since this may affect tear clearance.

Furthermore, when interpreting the results reported in this study, it has to be mentioned that dry eyes are difficult to evaluate. Dry eye symptoms have a complex and multifactorial aetiology and there is no single definitive diagnostic test to identify or classify the severity of dry eye disease. Tear production, turnover and volume can be estimated by several methods, but there is limited correlation between different tests (Sullivan et al. 2014). Accordingly, a combination of tests should provide a more reliable diagnosis and increase the specificity and sensitivity of dry eye diagnosis. This is why multiple dry eye tests were performed in this study.

In contrast to older literature, which suggests that excising a part of the orbicularis oculi muscle during upper blepharoplasty may cause dry eye problems (Rees 1975; Saadat & Dresner 2004; Prischmann et al. 2013), we did not find any differences between the skin only technique and the technique with additional muscle excision when evaluating objective dry eye tests and patient reported dry eye symptoms. In a split-face study (Kiang et al. 2014), where only skin was removed from one eye and skin was removed with muscle from the contralateral side, the patients only reported dry eye on the side where both skin and muscle were removed. In these cases, the mean amount of muscle removed was 9 mm or more while we removed no more than 3–4 mm of muscle. It is important to avoid excising too much tissue during surgery so as to avoid postoperative lagophthalmos since the latter significantly increases the risk of dry eye symptoms (Prischmann et al. 2013).

#### Clinical implications

Since long-term dry eye signs, and symptoms do not appear to differ between the techniques, the least invasive surgical technique should be used. In clinical practice, patients who attend a consultation for an upper blepharoplasty should be adequately informed about what to expect after surgery regarding dry eyes. According to the results of the current study, this should include that, in general, upper blepharoplasty does not induce long-term dry eye symptoms.

#### Conclusion

Upper blepharoplasty alleviates subjective dry eye complaints in the long term while, at the same time, it does not change the tear dynamics. Resecting an additional strip of orbicularis muscle did not influence the results.

## References

Baenninger PB, Voegeli S, Bachmann LM, Faes L, Iselin K, Kaufmann C & Thiel MA (2018): Variability of tear osmolarity measurements with a point-of-care system in healthy subjects—systematic review. *Cornea* **37**(7): 938–945.

Bartlett JD, Keith MS, Sudharshan L & Snedecor SJ (2015): Associations between signs and symptoms of dry eye disease: a

systematic review. *Clin Ophthalmol* **9**: 1719–1730.

Bron AJ, Abelson MB, Ousler G, Pearce E, Tomlinson A, Yokoi N, Paugh J (2007): Methodologies to diagnose and monitor dry eye disease: report of the Diagnostic Methodology Subcommittee of the International Dry Eye WorkShop (2007). *Ocul Surf* **5**(2): 108–152.

Bron AJ, Evans VE & Smith JA (2003): Grading of corneal and conjunctival staining in the context of other dry eye tests. *Cornea* **22**(7): 640–650.

Fagien S (2010): The role of the orbicularis oculi muscle and the eyelid crease in optimizing results in aesthetic upper blepharoplasty: a new look at the surgical treatment of mild upper eyelid fissure and fold asymmetries. *Plast Reconstr Surg* **125**(2): 653–666.

Feenstra RP & Tseng SC (1992): Comparison of fluorescein and rose bengal staining. *Ophthalmology* **99**(4): 605–617.

Floegel I, Horwath-Winter J, Muellner K & Haller-Schober EM (2003): A conservative blepharoplasty may be a means of alleviating dry eye symptoms. *Acta Ophthalmol Scand* **81**(3): 230–232.

Gomes JAP, Azar DT, Baudouin C, Efron N, Hirayama M, Horwath-Winter J, Kim T, Wolffsohn JS (2017): TFOS DEWS II iatrogenic report. *Ocul Surf* **15**(3): 511–538.

Gulyas G (2006): Improving the lateral fullness of the upper eyelid. *Aesthetic Plast Surg* **30**: 641–648; discussion 649–50.

Hamawy AH, Farkas JP, Fagien S & Rohrich RJ (2009): Preventing and managing dry eyes after periorbital surgery: a retrospective review. *Plast Reconstr Surg* **123**(1): 353–359.

Hollander MHJ, Contini M, Pott JW, Vissink A, Schepers RH & Jansma J (2019): Functional outcomes of upper eyelid blepharoplasty: A systematic review. *J Plast Reconstr Aesthet Surg* **72**(2): 294–309.

Jacobs LC, Liu F, Bleyen I, Gunn DA, Hofman A, Klaver CC, Uitterlinden AG, Nijsten T (2014): Intrinsic and extrinsic risk factors for sagging eyelids. *JAMA Dermatol* **150**(8): 836–843.

Kiang L, Deptula P, Mazhar M, Murariu D & Parsa FD (2014): Muscle-sparing blepharoplasty: a prospective left-right comparative study. *Arch Plast Surg* **41**(5): 576–583.

Lemp MA, Bron AJ, Baudouin C, Benitez Del Castillo JM, Geffen D, Tauber J, Foulks GN, Sullivan BD (2011): Tear osmolarity in the diagnosis and management of dry eye disease. *Am J Ophthalmol* **151**(5): 792–798.e1.

Maliborski A & Rozycki R (2014): Diagnostic imaging of the nasolacrimal drainage system. Part I. Radiological anatomy of lacrimal pathways. *Physiology of tear secretion and tear outflow. Med Sci Monit* **20**: 628–638.

Mathews PM, Karakus S, Agrawal D, Hindman HB, Ramulu PY & Akpek EK (2017): Tear osmolarity and correlation with ocular surface parameters in patients with dry eye. *Cornea* **36**(11): 1352–1357.

- Ong ES, Felix ER, Levitt RC, Feuer WJ, Sarantopoulos CD & Galor A (2018): Epidemiology of discordance between symptoms and signs of dry eye. *Br J Ophthalmol* **102**(5): 674–679.
- Prischmann J, Sufyan A, Ting JY, Ruffin C & Perkins SW (2013): Dry eye symptoms and chemosis following blepharoplasty: a 10-year retrospective review of 892 cases in a single-surgeon series. *JAMA Facial Plast Surg* **15**(1): 39–46.
- Rees TD (1975): The "dry eye" complication after a blepharoplasty. *Plast Reconstr Surg* **56**(4): 375–380.
- Rohrich RJ, Coberly DM, Fagien S & Stuzin JM (2004): Current concepts in aesthetic upper blepharoplasty. *Plast Reconstr Surg* **113**(3): 32e–42e.
- Rymer BL, Marinho DR, Cagliari C, Marafon SB & Procyanoy F (2017): Effects of Muller's muscle-conjunctival resection for ptosis on ocular surface scores and dry eye symptoms. *Orbit* **36**(1): 1–5.
- Saadat D & Dresner SC (2004): Safety of blepharoplasty in patients with preoperative dry eyes. *Arch Facial Plast Surg* **6**(2): 101–104.
- Schiffman RM, Christianson MD, Jacobsen G, Hirsch JD & Reis BL (2000): Reliability and validity of the Ocular Surface Disease Index. *Arch Ophthalmol* **118**(5): 615–621.
- Schulze S (2006): Discrepancy between objective measurement and subjective recognition of sicca syndrome before and after blepharochalasis operation for cosmetic or medical reasons. *Klin Monbl Augenheilkd* **223**(2): 131–133.
- Sullivan BD, Crews LA, Messmer EM, Foulks GN, Nichols KK, Baenninger P, Geerling G, Lemp MA (2014): Correlations between commonly used objective signs and symptoms for the diagnosis of dry eye disease: clinical implications. *Acta Ophthalmol* **92**(2): 161–166.
- Sullivan BD, Crews LA, Sonmez B, de la Paz MF, Comert E, Charoenrook V, de Araujo AL, Lemp MA (2012): Clinical utility of objective tests for dry eye disease: variability over time and implications for clinical trials and disease management. *Cornea* **31**(9): 1000–1008.
- Tong J, Lopez MJ & Patel BC. (2021): Anatomy, Head and Neck, Eye Orbicularis Oculi Muscle. In: Anonymous StatPearls. Treasure Island (FL): StatPearls Publishing LLC. Available at: <https://www.ncbi.nlm.nih.gov/books/NBK441907/>. (Accessed on 24 Feb 2021).
- van der Lei B, Timmerman IS, Cromheecke M & Hofer SO (2007): Bipolar coagulation-assisted orbital (BICO) septoblepharoplasty: a retrospective analysis of a new fat-saving upper-eyelid blepharoplasty technique. *Ann Plast Surg* **59**(3): 263–267.
- Vehof J, Sillevius Smitt-Kamminga N, Nibourg SA & Hammond CJ (2017): Predictors of discordance between symptoms and signs in dry eye disease. *Ophthalmology* **124**(3): 280–286.
- Vold SD, Carroll RP & Nelson JD (1993): Dermatochalasis and dry eye. *Am J Ophthalmol* **115**(2): 216–220.
- Whitcher JP, Shiboski CH, Shiboski SC, Heidenreich AM, Kitagawa K, Zhang S, Hamann S, ... Daniels TE and Sjogren's International Collaborative Clinical Alliance Research Groups (2010): A simplified quantitative method for assessing keratoconjunctivitis sicca from the Sjogren's Syndrome International Registry. *Am J Ophthalmol* **149**(3): 405–415.
- Willcox MDP, Argueso P, Georgiev GA, Holopainen JM, Laurie GW, Millar TJ, Papas EB, Jones L (2017): TFOS DEWS II tear film report. *Ocul Surf* **15**(3): 366–403.
- Wolff A, Joshi RK, Ekstrom J, Aframian D, Pedersen AM, Proctor G, Narayana N, Dawes C (2017): A guide to medications inducing salivary gland dysfunction, xerostomia, and subjective sialorrhea: a systematic review sponsored by the world workshop on oral medicine VI. *Drugs R.D* **17**(1): 1–28.
- Wolffsohn JS, Arita R, Chalmers R, Djalilian A, Dogru M, Dumbleton K, Gupta PK, Craig JP (2017): TFOS DEWS II Diagnostic Methodology report. *Ocul Surf* **15**(3): 539–574.
- Zhang SY, Yan Y & Fu Y (2020): Cosmetic blepharoplasty and dry eye disease: a review of the incidence, clinical manifestations, mechanisms and prevention. *Int J Ophthalmol* **13**(3): 488–492.

---

Received on April 21st, 2021.  
Accepted on September 22nd, 2021.

*Correspondence:*  
Maria H.J. Hollander, MD  
Department of Oral and Maxillofacial Surgery  
University Medical Center Groningen  
PO BOX 30.001  
9700 RB Groningen  
The Netherlands  
Phone: +31 50 3613841  
Fax: +31 50 3611136  
Email: [m.h.j.hollander@umcg.nl](mailto:m.h.j.hollander@umcg.nl)